

**Case introduction by Dr. med. Peter Herrmann**, Consultant in the Department of Septic Surgery, Osseous, Articular and Prosthesis Infections, Berufsgenossenschaftliche Unfallklinik, Ludwigshafen

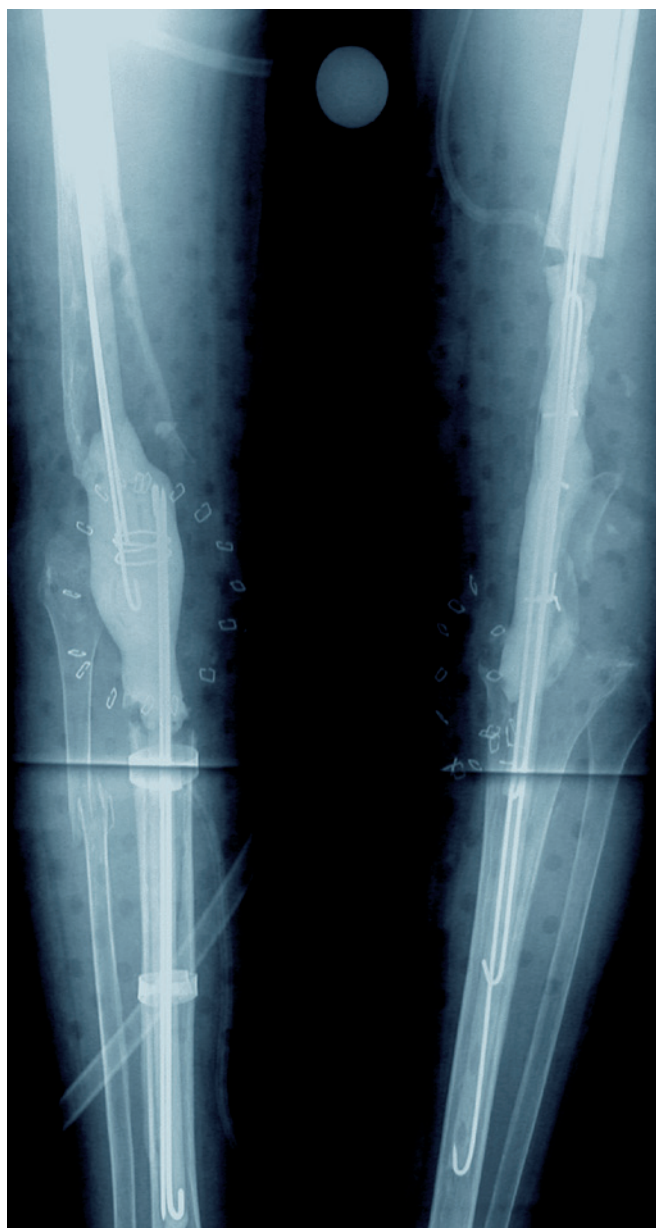
## Prosthesis infection of the knee joints on both sides

The infection of a **total knee joint replacement (knee TEP)** is one of the most severe complications in the field of joint replacement. Despite adhering to the strictest hygiene standards, the rate of infection in Germany is approximately 1%, according to figures from the National Reference Centre. Experts, however, view this figure as a rather optimistic estimation.

The progress of a prosthesis infection is worsened in the knee joint by the significant lack of soft tissue covering in comparison to the hip joint. In addition to the reconstruction of the joint mechanics, plastic surgery procedures in the knee joint are necessary in revision of a joint replacement.

Here, we describe the case of a female patient with rheumatoid arthritis who was assigned to us with an infection of revision prostheses in both knee joints and pronounced soft tissue defects. In this situation, the patient was in serious danger of losing both legs.

Anamnesis and findings on admission: A 68-year-old female patient who had suffered with rheumatoid arthritis for 20 years came to us for a consultation in March 2009. In 1999, she underwent total joint replacement of both knees due to arthrosis of the knee joints. In 2000, she underwent a change of inlay on the right. In May 2008, the total knee joint replacement was removed and a revision prosthesis was implanted. A periprosthetic infection has now also developed in the left knee joint. Since October 2008, the patient has undergone multiple operations with vacuum sealing of soft tissue defects on both extensor sides of the knees. The function of the extensor apparatus in the right knee joint was completely lost in the meantime. As an additional finding, the patient lost an ankle joint prosthesis on the left in 2005, due to



X-ray findings following removal on both sides of revision total knee joint replacement and insertion of spacers

infection, and received arthrodesis with an Ilizarov fixator.

In the initial consultation, we saw a very serious situation with infected total knee joint replacements on both sides with vacuum sealing dressings and with no extensor ability in the right knee joint. The microbiology findings yielded evidence of a *Staphylococcus aureus* (MSSA) infection on both sides. To preserve both legs, the following treatment concept was devised with the patient, who considers compliance and perseverance to be extremely important:

- Removal of both total knee joint replacements (knee TEP)
- Two-phase implantation of a knee fusion nail on the right and plastic closure using gastrocnemius muscle flaps
- Conditioning of the soft tissue over the spacer in the left knee joint, initially with mesh graft covering
- Two-phase implantation of a revision total knee joint replacement on the left

**Progress**

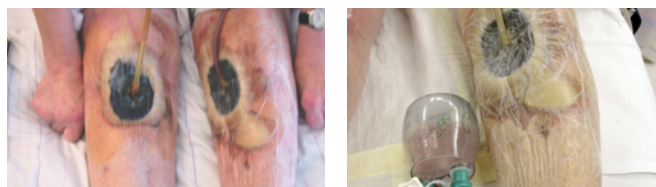**23 March 2009**

Explantation of the total knee joint replacement on the right with significant loss of bone, following removal of the cement. Insertion of a spacer with self-constructed place-holders with medullar components and cerclages. In this procedure, only lavage and covering with Coldex was carried out on the left knee joint, caused by the high level of strain during the operation.

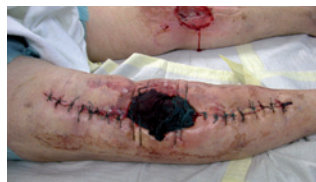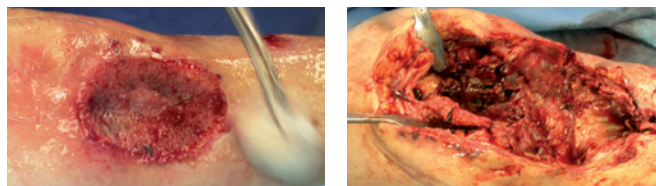
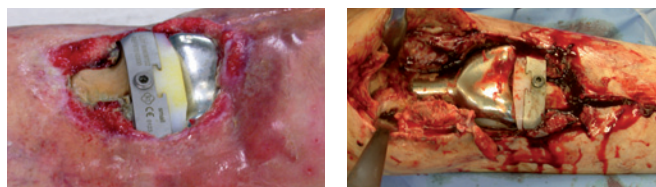
**25 March 2009**

Plastic closure of the right knee with medial gastrocnemius muscle flaps. Removal of the total left knee joint replacement and insertion of a spacer. Mesh graft skin graft over the head of the left tibia.

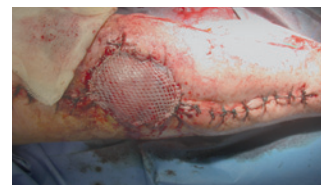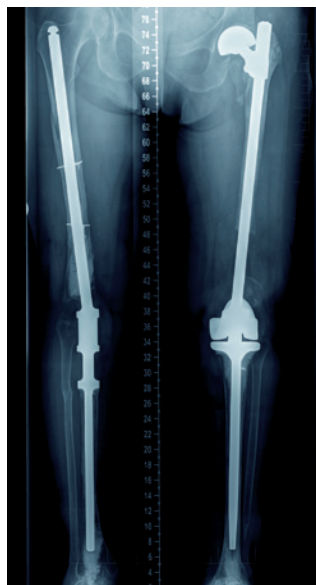
The patient was discharged following consolidation of the soft tissue. Special implants were ordered from the company LINK, for treatment with a knee fusion nail on the right and a total knee joint replacement on the left in accordance with the X-ray outlines. Due to the patient’s rheumatoid arthritis and the long fixation distance in the femur, the option of implantation of total hip joint replacement at a later date must be left open. A decision was therefore taken to ensure compatibility with MEGASYSTEM-C, manufactured by LINK, with the possibility of total hip joint replacement using the push through procedure.



Findings on admission: exposed total knee joint replacement with vacuum sealing of both legs



Above left: total right knee joint replacement following removal of the vacuum sealing. Above right: total right knee joint replacement following debridement of soft tissue. Middle left: operation site on the left during the first operation. Middle right: right knee following removal of the total knee joint replacement. Bottom left: findings for the right knee following the first procedure



Above: right knee following plastic closure over the spacer. Left: complete images of the legs with the patient standing, dated 11 March 2010; X-ray findings with new implants in both legs

**21 May 2009**

The patient was readmitted.

**29 May 2009**

Implantation of a LINK knee fusion nail with balancing of the defect along its length, lifting and refixing of the gastrocnemius muscle flap during this.

**15 June 2009**

Fitting of a coupled Link revision total knee joint replacement with femoral MEGASYSTEM-C shaft. Refixation of the damaged area of attachment of the patellar ligament with Mitek suture anchors. Soft tissue covering using medial gastrocnemius muscle flaps. Mobilisation of the patient with weight-bearing on the right leg. Left knee joint immobilised in a Softcast cylinder cast due to the refixed patellar ligament.

**15 July 2009**

The patient was discharged.

**6 September 2009**

The patient fell onto her left hip joint at home and sustained a medial fracture of the neck of the femur.

**7 September 2009**

The patient was readmitted.

**8 September 2009**

K-wire extension of the calcaneum of the left leg. A custom-made LINK MEGASYSTEM-C hip module was ordered, with caudalised neck of the femur for treatment with a dual-head prosthesis, using the push through procedure.

**16 September 2009**

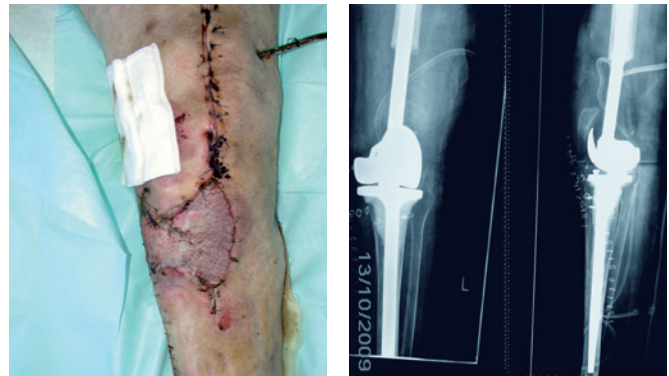
Removal of the wire extension of the calcaneum.

**28 September 2009**

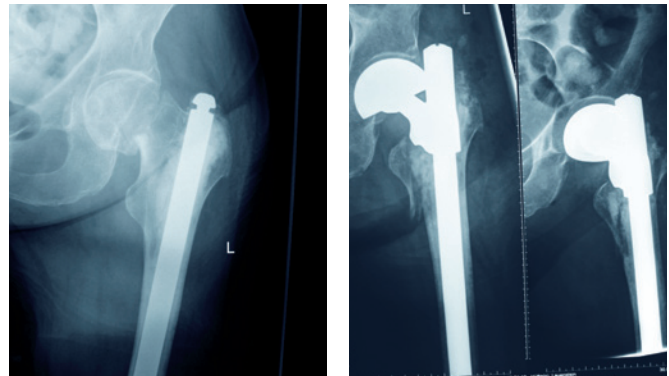
Resection of the head of the left femur and implantation of a dual-head attachment hip joint extension module, custom-made in the MEGASYSTEM-C by LINK. The special module was necessary to enable the hip module to be positioned on the higher end of the femoral section of the knee joint replacement. The patient could then even be mobilised with full weight bearing. Wound healing was slow, however free of complications on the whole, with no further revisions.

**17 October 2009**

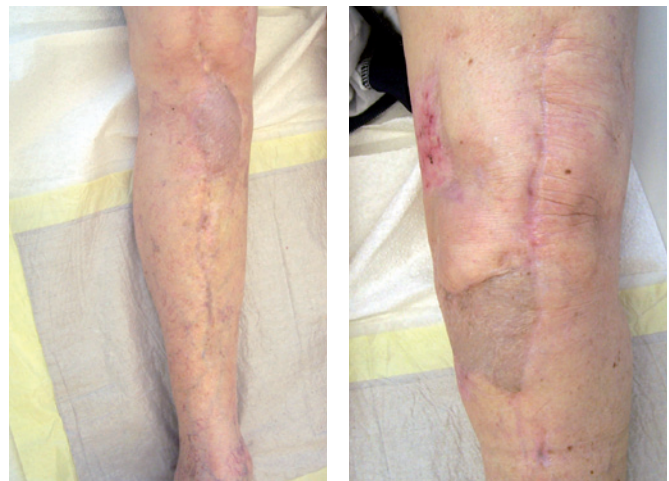
The patient was discharged home. Rehabilitation was car-



Left: left leg after the operation. Right: X-ray image after the operation on 15 June 2009; left knee after the operation



Left: medial fracture of the neck of the femur. Right: left hip after the operation



The soft tissue over both knee joints are covered in a stable manner, the multiple split-skin sampling sites are still covered with unstable scars during epithelialisation, however in a normal condition on the whole

ried out near the patient's home from 5 November 2009.

**10 March 2010**

The patient returned for an appointment for a follow-up check on progress. The patient was mobilised on a mobile walking frame with full weight bearing on both legs.

**Conclusion**

From a very serious situation with combined total joint replacement and soft tissue infection with loss of bone and soft tissue in both legs, the patient was finally able to bear full weight and full sensation was maintained in both legs, due to the insertion of modern custom-made implants and plastic surgery procedures with local flap repair.

The patient's progress should indicate and reinforce the idea that such solutions are possible using a combination of soft tissue reconstruction and revision total joint replacement. The move to constant vacuum sealing of the exposed joint replacement, which must be deemed to be chronically infected and not able to be saved, is not a solution, but simply a delay in treatment that merely costs the patient time. Against the background of this progress, it seems that the indication for amputation at the thigh frequently expressed to the patient was a premature declaration of the failure of modern joint replacement.

The fact that the option for later hip joint replacement should certainly be considered when choosing an implant, in the case of mega implants in the knee joint, was clearly proven much earlier than wanted by the case described, due to the fracture of the neck of the femur suffered by the patient.

**Publication details**

**Publisher**

Waldemar Link GmbH & Co. KG · Helmut D. Link

**Editing** (responsible): Heike Urbschat

Tel.: +49 (0)40 5 39 95-0 · E-Mail: redaktiondirectLINK@linkhh.de

**Realization/Production:** medienärzte – Agentur für Gesundheitskommunikation · Hamburg · www.medienaeerzte.de

**Photos:** Dr. Peter Herrmann, BG-Unfallklinik, Ludwigshafen

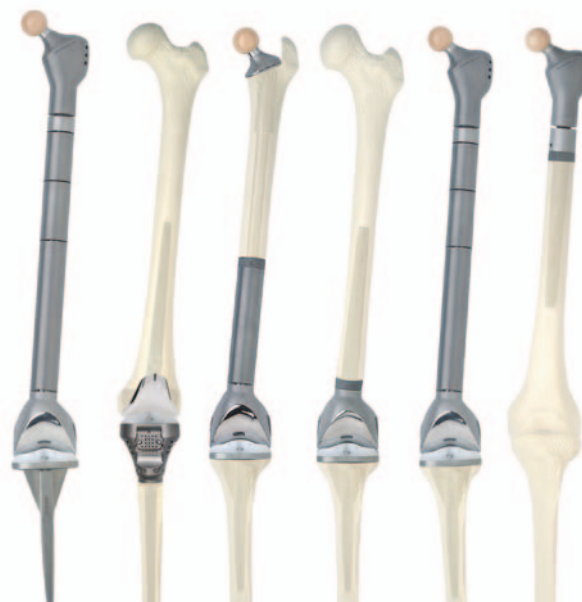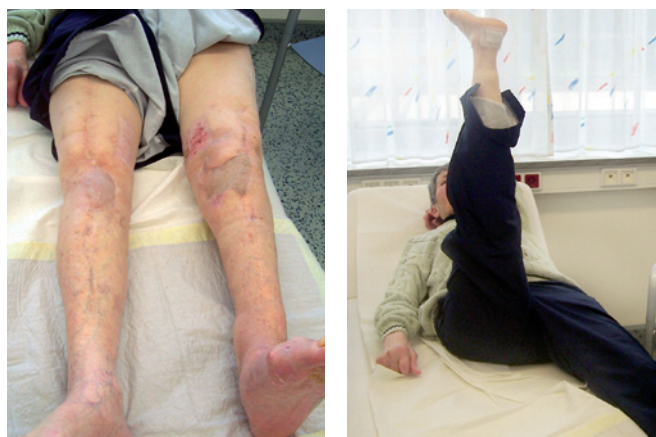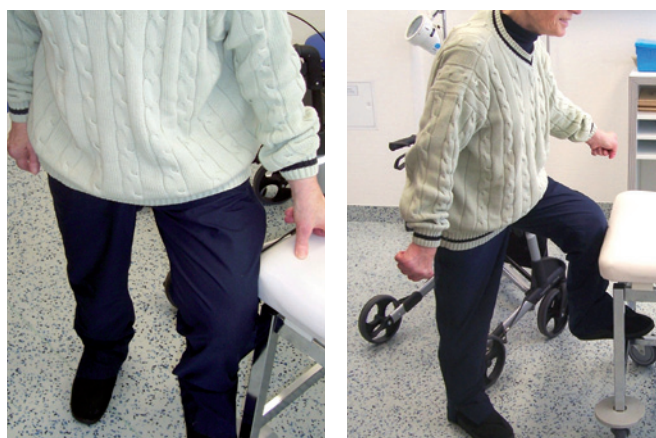**Printing:** Nehr Offsetdruck Media · Hamburg

**Waldemar Link GmbH & Co. KG**

**Barkhausenweg 10 · D-22339 Hamburg, Germany**

Tel.: +49 (0)40 5 39 95-0 · Fax: +49 (0)40 5 38 69 29

redaktiondirectLINK@linkhh.de · www.linkhh.de



Above: Despite the very serious situation at the outset, the patient was able to bear full weight and full sensation was maintained in both legs, due to the insertion of modern specialized implants and plastic surgery procedures with local flap repair

Below: overview of the modular MEGASYSTEM-C reconstruction system from LINK for tumour and trauma surgery